

## Cleidocranial Dysplasia - A Case Report And Review of Literature

Dr. Nivedita Ckvs<sup>1</sup>, Dr. Ajit D. Dinkar<sup>2</sup>, Dr. Manisha Khorate<sup>3</sup>,  
Dr. Sonam Khurana<sup>4</sup>

<sup>1</sup>Oral Medicine And Radiology Department, Goa Dental College And Hospital, Goa, India

<sup>2</sup>Professor and Head, Oral Medicine and Radiology Department, Goa Dental College and Hospital, Goa, India

<sup>3</sup>Assistant Professor, Oral Medicine and Radiology Department, Goa Dental College and Hospital, Goa, India

<sup>4</sup>Oral Medicine and Radiology Department, Goa Dental College and Hospital, Goa, India.

---

**Abstract:** Cleidocranial dysplasia (CCD) is an autosomal dominant disease characterized by general dysplastic bone formation manifested in typical malformations in the skull, the pelvis and the thoracic region. It is caused by mutation in the gene on 6p21 encoding transcription factor Core Binding Factor Subunit Alpha 1 (CBFA1) or Runt related transcription factor 2 (RUNX2), which is involved in the differentiation of osteoblasts and bone formation. This paper reports a case of cleidocranial dysplasia in a 28 year old female patient and review of literature with a brief emphasis on the role of CBFA1 gene in the pathogenesis of CCD. Radiographs of the skull, teeth and clavicles were the diagnostic evidences of our case.

**Keywords:** CBFA gene; Clavicle; Cleidocranial Dysplasia; Supernumerary Teeth; Open fontanelle.

---

### I. Introduction

Cleidocranial dysplasia (MIM 119600) is a rare autosomal dominant disease with a wide range of variability. The phenotype is characterized by general dysplastic bone formation manifested in typical malformations in the skull, the pelvis and the thoracic region [1]. The disorder was originally thought to involve bones of intramembranous origin only, namely the bones of the skull, clavicles and flat bones, hence the term, "cleidocranial". Later it was known that bones of endochondral ossification are also affected and it is a generalized disorder of many skeletal structures [2]. Early diagnosis of cleidocranial dysplasia is important as prompt intervention can greatly influence the treatment outcome by restoring the patient's dental aesthetics and function. Both dominant and recessive patterns of inheritance have been described [3]. However, 40% of the cases appear spontaneously with no apparent genetic cause [4]. CCD is present at a frequency of one in 1,000,000 individuals worldwide [5].

Cleidocranial dysplasia (CCD) was first described in 1765 although, according to Soule, the first true case was not described until 1870 by Cutter [6]. One of the most colourful families, descendants of a Chinese named Arnold, was described by Jackson. He traced 356 members of this family, 70 of whom were affected with the so called "Arnold Head" that is now confirmed as CCD [7]. Pierre Marie and Paul Sainton in 1898 coined the term dysostose cleido-cranienne hereditaire (hereditary cleidocranial dysostosis) for this condition and were the first to describe several cases of the disease and associate it with patterns of inheritance [6,7]. In 1962, Kallialla suggested a genetic mutation as an etiology; however, in that same year Forlan concluded that cleidocranial dysplasia was both an autosomal dominant inherited disease and a disease caused by mutation due to external interferences during fetal life [6]. This paper presents the clinical and radiological features in a rare case of cleidocranial dysplasia.

### II. Case Report

A 28 year-old female patient presented with the chief complaints of mobile and multiple missing teeth. No relevant medical or drug history was noted. There was no history of exposure to teratogenic agents, cytotoxic drugs and viral infections.

General physical examination demonstrated a medium build, short stature (149 cms), sloping and shrugged shoulders which were easily apposable. Shortening of the thumb and the fifth finger was noted. She also presented with brachymetatarsia bilaterally with broad thumbs and toes. Extraoral examination revealed brachycephaly and a prominent forehead, with ocular hypertelorism. Frontal, parietal and occipital bossing was present, giving the skull a large globular shape. Depressed nasal bridge and mid-facial hypoplasia was evident. Mandibular prognathism, prominent chin, straight facial profile with competent lips was seen.

Intraoral examination revealed multiple missing permanent teeth with over retained deciduous teeth, narrow high vault palate, anterior and posterior cross bite. Class 3 molar relationship was seen bilaterally. She

also had a slurred speech. Radiological investigations included chest radiograph, hand-wrist and foot radiographs, Orthopantomogram, lateral and postero-anterior view of the skull.

Radiographic features:

**Chest radiograph:** There was bilateral absence of clavicles, cone-shaped thorax, low placed scapulae, and spine appeared to be normal.

**Foot radiograph:** Broad halluces with hypoplastic distal phalanges, short middle phalanges and resorption of the distal phalynx of the great toe were seen with shortening of the 4<sup>th</sup> metacarpal suggestive of brachymetatarsia.

**Hand wrist radiograph:** Hypoplastic terminal phalanges, shortening of the middle phalynx of second and fifth finger and narrowing of the metacarpals.

**Orthopantomograph:** Multiple impacted permanent and supernumerary teeth in the incisor and bicuspid regions of the maxilla and mandible and over retained deciduous teeth. Follicular spaces of some impacted teeth were enlarged in the mandibular left parasymphysis region, suggesting cystic transformation. Root apices of the mandibular supernumerary teeth were seen to approximate the inferior border of the mandible bilaterally in the parasymphysis region. Parallel sided ascending ramus seen bilaterally with upward pointing of the coronoid process. Rounded contour of the angle of the mandible was evident. Thin zygomatic arch was also seen.

**Postero-anterior view:** Brachycephaly of the skull with light bulb shaped appearance. Craniofacial disproportion evident, patent sutures with wide separation of the sagittal suture which appears broad with irregular margins, flattening of the skull on the superior surface, inner and outer tables of the skull cannot be well differentiated. Agenesis of frontal sinus and hypoplastic mastoid process seen bilaterally. Nasal septum appears deviated to the right side. Hypertrophy of the left inferior turbinate noted along with deficient zygomatic bone and hypoplastic maxillary sinus.

**Lateral skull view:** Gonial angle is replaced by a rounded contour of the mandible referred to a banana shape. Widening of the coronal suture evident with patent anterior fontanelle. Wormion bone evident at the anterior fontanelle region and in the lambdoid suture region which are formed by secondary ossification centres. Sphenoid sinus shows complete opacification and obliteration of the mastoid air cells are noted. Maxillary retrognathism with shortened nasal bone was evident.

Pure tone audiometry test revealed mild conductive hearing loss on right ear and left ear showed moderate conductive hearing loss. After completing all the necessary investigations, the patient was confirmed as having cleidocranial dysplasia. She is currently being treated by a team of orthodontists, oral surgeons and prosthodontists.

### III. Discussion

CCD is caused by mutation in the gene on 6p21 encoding transcription factor Core Binding Factor Subunit Alpha 1 (CBFA1) or Runt related transcription factor 2 (RUNX2). RUNX2 is a part of the Fibroblast Growth Factor (FGF) and Bone Morphogenetic Protein (BMP) signaling pathways in tooth and bone development respectively. FGF and BMP4 induce both Msx1-dependent and Msx1-independent signalling pathways in early tooth development [8].

The core-binding factor (CBF) transcription factors are a family of heterodimeric proteins of two unrelated sub-units comprising a DNA binding  $\alpha$  subunit and a non-DNA-binding  $\beta$  subunit. The mammalian CBF $\alpha$  subunits are encoded by three distinct genes (CBFA1, CBFA2 and CBFA3) and a common  $\beta$  subunit is encoded by the CBF $\beta$  gene [9]. CBFA1 plays an important role in the epithelial-mesenchymal interactions that control progressive tooth morphogenesis and histodifferentiation of the epithelial enamel organ; levels are highest before the development of the tooth crown but taper after completion of crown formation [10]. Deletions, insertions and a missense mutation involving the CBFA1 gene have been identified in patients with CCD. Heterozygous loss of function is sufficient to produce the characteristic clinical findings [11]. About one-third of CCD patients do not have RUNX2 mutations. Recent studies have identified multiple supernumerary teeth, hypoplastic clavicles, an open fontanelle, and an elongated coronoid process in mice with Cebpb deficiency. These phenotypes coincide with signs of CCD in humans; consequently, a relationship between cebpb and CCD is suspected. Cebpb has been demonstrated as a key regulator for Runx2, which was related to occurrence of most but not all CCD cases [7].

Loss of CBFA1 function affects both membranous and endochondral bone formation. The defective membranous bone formation in CCD is consistent with a key role for CBFA1 in osteoblast differentiation. Stunted growth and metaphyseal changes seen in patients with CCD also suggest, however, that CBFA1 is important for endochondral bone formation. Action of CBFA1 in the perichondrium is necessary for differentiation of chondrocytes to hypertrophy in the underlying cartilage, both at the time of establishment of ossification centers as well as during longitudinal growth. The expression of CBFA1 in mesenchymal progenitor cells makes it likely that CBFA1 is also involved in early patterning [11].

In mice, the *RUNX2* gene is also expressed in the mesenchyme of the dental follicle and periodontal ligament before tooth eruption. Haploinsufficiency of *RUNX2* in mice impairs the differentiation and recruitment of osteoclasts together with reduction in the capacity of periodontal ligament cells to induce active osteoclastic differentiation. These processes could, in part, account for delayed tooth eruption patterns in humans with CCD [10]. The lack of cellular cementum is also considered to be one of the factors for uneruption of teeth in CCD. It is also suggested that remnants of the dental lamina are activated to form supernumerary teeth in CCD patients when mineralization of the crowns of the permanent teeth is complete. The presence of multiple supernumerary teeth may cause mechanical obstruction and may be the chief factor for the impaction of permanent teeth observed in CCD [2].

The clinical and radiographic abnormalities seen in CCD are: [4, 1, 12-14]

<b>Skull and face</b>	Delayed or deficient closure of fontanelles with persistent sutures. Brachycephaly, hypertelorism, presence of wormian bones. Frontal bossing with high forehead is seen. Underdeveloped paranasal sinuses, persistent metopic suture, non-union of mandibular symphysis, hypoplastic middle third of the face can present a bird-face appearance. There is broad base of the nose as there is a failure of the nasal bone to ossify leading to depression in the bridge of nose. Shortened skull base, basilar kyphosis.
<b>Ears</b>	Conductive deafness is seen in some cases due to structural abnormality of the ossical leading to middle ear condition which is often associated with dense sclerosis of petrous and mastoid temporal bones. There is a predisposition to otitis media.
<b>Thorax and shoulders</b>	Aplasia or hypoplasia of clavicles, sloping shoulders. Chest may be narrowed or funnel shaped with small and deformed scapulae. Supernumerary ribs may also be present.
<b>Pelvis and hips</b>	A wide symphyseal space presents chef's hat appearance, delayed closure of the symphysis pubis. Coxa Vara the deformity of the hip where the angle formed between the head and neck of the femur and its shaft is decreased usually defined as less than 120 degrees. Hypoplasia of the iliac bone is seen. Widened sacro-iliac joint and triradiate cartilage.
<b>Spine</b>	Scoliosis, kyphosis, cervico-thoracic neural arch defect, posterior wedging of thoracic vertebrae, lumbar spondylolysis, spina bifida occulta.
<b>Hands</b>	The fingers are short and tapered, except for a long index finger, due to a long second metacarpal, and clinodactyly of the fifth finger has been reported. Hands with finger length asymmetry due to extra epiphysis in metacarpels II and V and multiple cone-shaped epiphysis. Hypoplastic terminal phalanges with shortened middle phalanges.
<b>Ankles and feet</b>	Shortened calcaneus, narrowed talus, forefoot deformities similar to those seen in the hands
<b>Limbs</b>	Limbs may be short and genu valgum are seen. There may be absence or short fibula and radius.
<b>Teeth and jaws</b>	Delayed exfoliation of primary teeth, delayed eruption of permanent teeth. Multiple impacted supernumerary teeth and malocclusion, crown and root anomalies, partial or complete absence of cellular cementum, cleft or narrow high-arched palate, dentigerous cysts caused by impacted teeth, coarse trabecular pattern of the jaws and hypoplasia of the muscles. The teeth may be small, irregular spaced and crowded showing aplasia, malformation, enamel hypoplasia.

Patients have normal intelligence and generally short stature, with a head circumference at the upper limit of normal. Other occasional findings include neurological and/or vascular signs caused by pressure of the clavicular remnants on the brachial plexus or subclavian artery, or by syringomyelia, which has an association with CCD [14]. Mc Namara et al (1999) in their study stated the possible influence of muscle action on bone form in this syndrome. Muscle attachments to the clavicles may be dysplastic, leading to distortion of the neck. There may be a thickening of the ascending ramus on the lingual side between the inferior dental canal and the internal oblique ridge. Coronoid process is slender, pointed often facing upwards and posteriorly. The activity of temporalis muscle may have a role in its upward and forward direction. It is accepted that in these cases there is a generalized reduction of growth potential as well as skeletal immaturity. Muscular development may be influenced by this effect. The narrow ring of bone formed by the zygomatic arch and the squamous temporal bone, as a result of hypoplasia of the zygomatico-facial complex, may constrict the temporalis muscle and so affect the form of the ascending ramus [3]. Common complications of CCD reported are pes planus, genu valgum, shoulder and hip dislocation, recurrent sinus infections, upper airway complications, recurrent ear infection, hearing loss, dental caries, osteomyelitis of the jaw bones and respiratory distress in early infancy which may be experienced because of narrow upper thoracic diameter [15].

Sequence analysis, followed by deletion/duplication analysis, can be considered for diagnostic confirmation, particularly if the findings do not meet clinical and radiologic diagnostic criteria [5]. Serum alkaline phosphatase activity has been observed to be consistently reduced in patients suffering from CCD [2] though in our patient it was found to be in the normal range. Radiology plays an important role in the diagnosis of this syndrome. Osseous findings are present early and may be detected later in the 1st trimester. Early prenatal ultrasound diagnosis of CCD is possible [13].

The differential diagnosis of CCD includes Crane-Heise syndrome, mandibuloacral dysplasia, pycnodysostosis, Yunis-Varon syndrome, CDAGS syndrome (craniosynostosis, anal anomalies, and prokeratosis) and hypophosphatasia etc. These conditions may share some characteristics with CCD [5] Treatment is often directed at orthopaedic correction which includes correcting multiple dislocated shoulders, radial head or hips. If bone density is below normal, treatment with calcium and vitamin D supplementation should be considered [8]. Three distinct and contrasting approaches have been suggested in the literature for dental management: The **Toronto-Melbourne approach** advocates a series of surgical procedures, initially involving the removal of the deciduous teeth under endotracheal general anaesthesia, with its timing dependent on appropriate root development of the permanent teeth; **Belfast-Hamburg approach** aims to limit the inescapable need for extensive surgery to a single episode, designed to remove all deciduous and supernumerary teeth and to expose all unerupted teeth simultaneously. The **Jerusalem approach** takes into account four principal aspects that should be considered in its comprehensive approach to treatment. These aspects may be listed as follows: (1) the clinical features of the dentoalveolar structures in the disease, (2) the surgical measures needed to overcome them, (3) the planning of appropriate orthodontic treatment strategy to meet the demands of the unusual circumstances, and (4) concentrating initial efforts towards bringing anterior teeth into the mouth early, for the patient's" self-image [16].

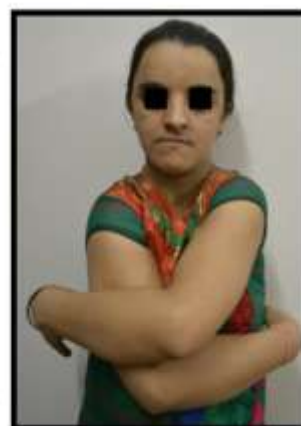**Figures**



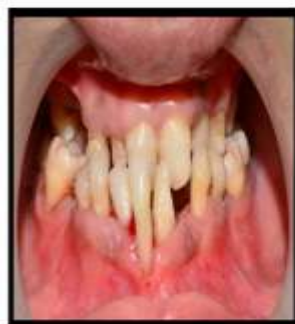**Fig No 1:**



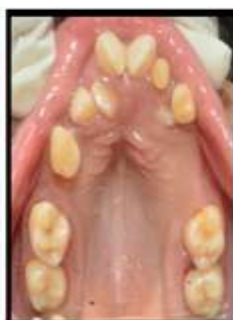**Fig No 2:**



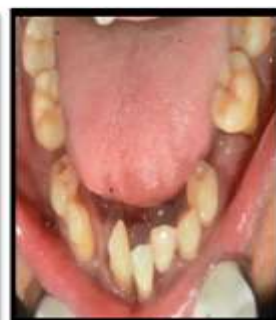**Fig No 3:**



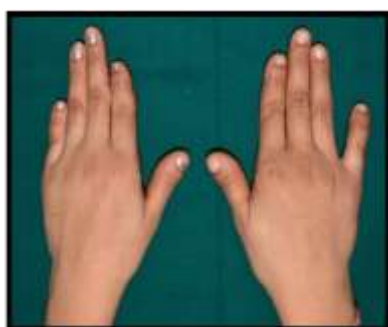**Fig No 4a:**



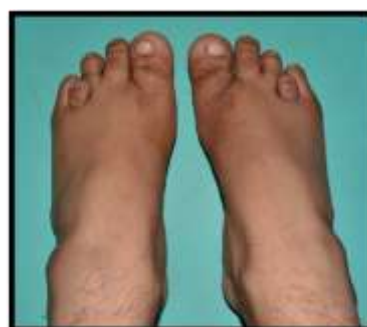**Fig No 4b:**



**Fig No 4c:**



**Fig No 5:**



**Fig No 6:**

**Figure 1:-** Shows short stature of the patient.

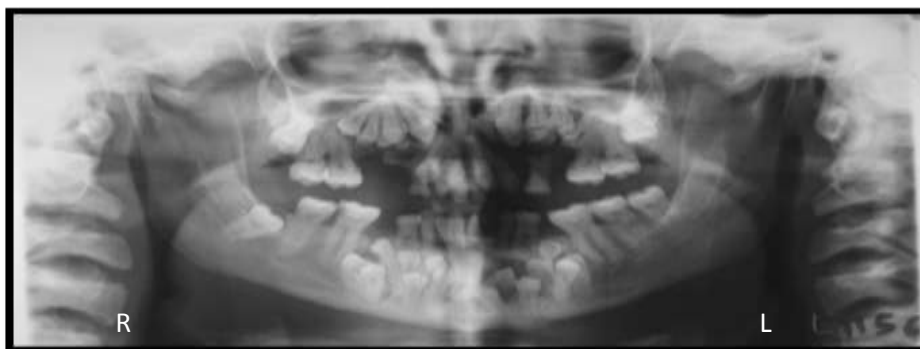
**Figure 2:-** Extra-oral photograph showing prominent forehead, hypertelorism, depressed nasal bridge.

**Figure 3:-** Adducted shoulders by the patient, which were easily apposable.

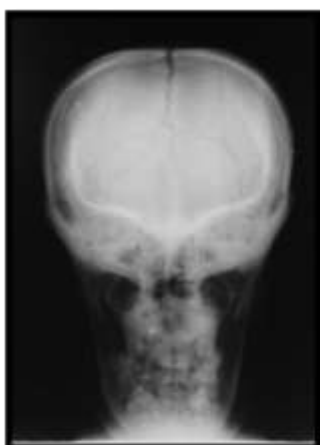
**Figure 4(a,b,c):-** Intra-oral photographs

**Figure 5:-** Shortening of the thumb and the fifth finger seen.

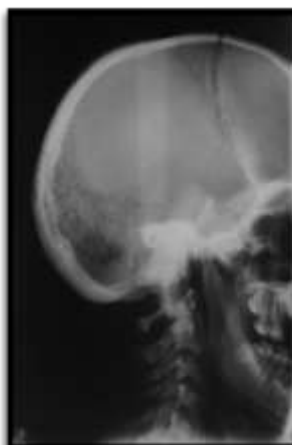**Figure 6:-** Brachymetatarsia seen bilaterally with broad thumbs and toes



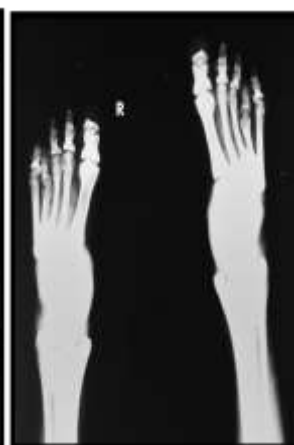**Fig No 7:**



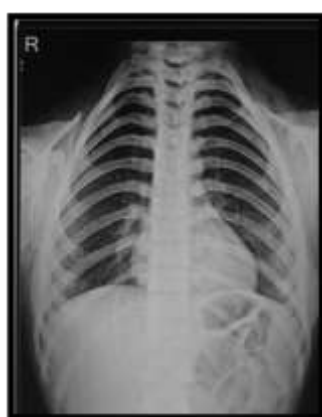**Fig No 8:**



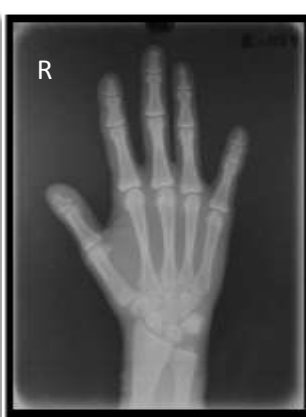**Fig No 9:**



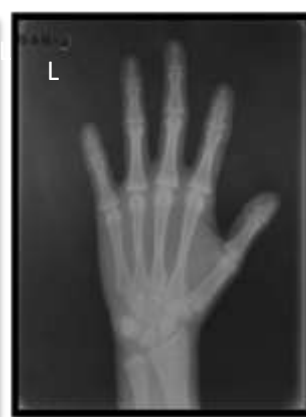**Fig No 10:**



**Fig No 11:**



**Fig No 12a:**



**Fig No 12b:**

**Figure 7:-** Orthopantomogram shows multiple impacted permanent and supernumerary teeth in the incisor and bicuspid regions of the maxilla and mandible with over-retained deciduous teeth. Parallel sided ascending ramus seen bilaterally with upward pointing of the coronoid process.

**Figure 8:-** Postero-anterior view of skull shows wide separation of sagittal suture with broad and irregular margins and agenesis of frontal sinus.

**Figure 9:-** Lateral skull view showing wide open sutures with wormion bone.

**Figure 10:-** Foot radiograph showing broad halluces with hypoplastic distal phalanges. Short middle phalanges and brachymetatarsia is also evident.

**Figure 11:-** Postero-anterior view of chest shows bilateral absence of clavicles, cone-shaped thorax and low placed scapulae.

**Figure 12(a and b):-** Hand wrist radiograph showing hypoplastic terminal phalanges and narrowing of the metacarpels.

#### **IV. Conclusion**

In conclusion, dentists should be aware of these findings in order to diagnose CCD at an early stage so as to provide early treatment for an aesthetically satisfying facial appearance along with psychological benefit and better life style to the patients.

#### **References**

- [1]. Ilan Golan, Uwe Baumert, Paul Held, Stefan Feuerbach, Dieter Mubig. Radiological Findings and Molecular Genetic Confirmation of Cleidocranial Dysplasia. *Clinical Radiology*, 2002; 57(6): 525-9.
- [2]. Manjunath K, Kavitha B, Saraswathi TR, Sivapathasundharam B, Manikandhan R. Cementum analysis in cleidocranial dysostosis. *Indian Journal of Dental Research*. 2008; 19(3): 523-6.
- [3]. McNamara CM, O' Riordan BC, Blake M, Sandy JR. Cleidocranial dysplasia: radiological appearances on dental panoramic radiography. *Dentomaxillofacial Radiology*. 1999; 28: 89-97.
- [4]. Mohan RPS, Suma GN, Vashishth S, Goel S. Cleidocranial dysplasia: clinico-radiological illustration of a rare case. *Journal of Oral Science*. 2010; 52(1):161-166.
- [5]. Londono RM, Lee B: University of Washington, Seattle. Cleidocranial Dysplasia-Genes Reviews, NCBI Bookshelf [Internet]. [Cited 2006 Jan 3].
- [6]. Newsha Azizi, Terence Perrault, Rosanne Gregory. Cleidocranial dysplasia: A case report. *Clinical Chiropractic*, 2010; 13: 275-279.
- [7]. Nur Mohammad Monsur Hassan, Abhayjit Dhillon, Boyen Huang. Cleidocranial dysplasia: Clinical overview and genetic considerations. *Pediatric Dental Journal*. 2016; 1-6.
- [8]. Patil PP, Barpande SR, Bhavthankar JD, Humbe JG. Cleidocranial Dysplasia: A Clinico-radiographic Spectrum with Differential Diagnosis. *Journal of Orthopaedic Case Reports*. 2015; 5(2): 21-24.
- [9]. Otto F, Thornell AP, Crompton T, Denzel A, Gilmour KC, Rosewell IR et al. Cbfa1, a candidate gene for cleidocranial dysplasia syndrome, is essential for osteoblast differentiation and bone development. *Cell*, 1997 May 30; 89(5):765-771.
- [10]. Tina Roberts, Lawrence Stephen, and Peter Beighton. Cleidocranial dysplasia: a review of the dental, historical, and practical implications with an overview of the South African experience. *Oral Surg Oral Med Oral Pathol Oral Radiol*. 2013; 115(1): 46-55
- [11]. Mundlos S, Otto F, Mundlos C, Mulliken JB, Aylsworth AS, Albright S et al. Mutations Involving the Transcription Factor CBFA1 Cause Cleidocranial Dysplasia. *Cell*, May 30 1997; 89:773-79.
- [12]. Gokhan Ozkan, Aydan Kanli. Clinical and radiological manifestations of cleidocranial dysplasia: A case report. *Indian journal of dentistry*. 2013; 4:174-177.
- [13]. Ramadoss T, Pravda C. Cleidocranial Dysplasia - Report of a rare case. *Indian Journal of Dentistry*.2013; 4:44 -47.
- [14]. Verity Currall, Rachel Clancy, Donna Dimond, Rouin Amirfeyz, Chris Kershaw, Martin Gargan. Cleidocranial dysplasia. *Current Orthopaedics*. 2007; 21:159-162.
- [15]. Furuuchi T, Kochi S, Sasano T, Iikubo M, Komai S, Igari K. Morphologic characteristics of masseter muscle in cleidocranial dysplasia: A report of 3 cases. *Oral Surg Oral Med Oral Pathol Oral Radiol Endod* 2005; 99:185-90.
- [16]. Adrian Becker, Joshua Lustmann, Arye Shteyer. Cleidocranial dysplasia: Part 1-General principles of the orthodontic and surgical treatment modality. *American Journal of Orthodontics and Dentofacial Orthopedics*. 1997; 111(1): 28-33.